CASE REPORT

Complex Malformations of the Lower Extremities – A Case Report

Dhan Raj Bagri*, Shashi Kant Meena, Vishnu Pansari*****

ABSTRACT

Introduction: Malformations of the lower extremities like fibular hemimelias, congenital femoraldeficiencies, congenital femoral hypoplasia and tibial hemimelias are rare and complex limb defects. Deformity or a defect of the femur termed proximal femoral focal deficiency (PFFD) previously, is being referred as congenital femoral deficiency now. The etiology is unknown, appropriate classification and management are yet being framed; especially in neonates.

Case Report: We are reporting a case affected by Complex Congenital Femoral Deficiency; This report is unique as only one of the twins was affected, suggesting against genetic ordevelopmental hypothesis.

Conclusions: We are more interested in management issues like applying the classification, counseling of parents and multi disciplinary team-based approach. We recommend to develop an inter departmental protocol for managing such cases.

Key Word: proximal femoral focal deficiency, PFFD, Complex Congenital Femoral Deficiency

Malformations with deficiencies of the lower extremities are rare anomalies hypothesized to be the result of toxic influences during pregnancy between 4th to 12th week of gestation (when extremities are created and differentiated;nature, duration of action and aggressiveness of the noxeun known) or genetic origin; with incidence of approximately 18 in 100,000 newborns. The most common deficiencies are fibular hemimelias, followed by congenital femoral deficiencies and tibial hemimelias. Hemimelias are often associated with ray defects & deficient toes[1]. Isolated congenital pseudarthrosis of the tibia is extremely uncommon with diagnosis established in an infant who has just started walking. Congenital femoral hypoplasia is a rare but complex limb defect, ranging from simple shortening of the femur to complete femoral agenesis.It is main congenital defect in 4 conditions: a) proximal femoral focal deficiency (PFFD); b) femoral hypoplasia unusual facies syndrome (FHUFS); c) femur/fibula/ulnar hypoplasia (FFU); and d) limb/pelvis-hypoplasia/aplasia syndrome[2]. If there is a deformity or a defect of the femur, the proximal part is always affected making the term "proximal femoral focal deficiency" (PFFD) used to be common, these days a more general term "congenital femoral deficiency" (CFD) is used.

The unknown etiology, appropriate classification and appropriate management are the issues of importance. We are reporting a case affected by lower limb malformation; the other twin being normal suggests against genetic or developmental hypothesis. The management issues involved in such cases also need to be addressed.

CASE REPORT

A primipara mother aged 20 years gave birth to twin children after 2 yrs of married life through caesarean section. Indication for caesarean was malpresentation. The antenatal history is normal except for leaking per vaginum of 24 hours. Mothers HIV and VDRL were negative. She has no history of hypertension and was

*Assistant Professor, **Senior Registrar, ***Associate Professior
Department of Pediatrics, Sir Padampat Mother and Child Health Institute
J K Lon Hospital, SMS Medical College, Jaipur.
Corresponding Author :
Dr. Dhan Raj Bagri
Assistant Professor, Department of Pediatrics, Sir Padampat Mother and Child Health Institute
J K Lon Hospital, SMS Medical College, Jaipur.
E-mail : meena.drdhanraj6@gmail.com
Contact No. : 9116772633

euthyroid. She was vaccinated for tetanus during pregnancy and antenatal checkups were done but only one antenatal ultrasound was done 2 days before delivery. There is no similar family history in maternal or paternal ancestors.

Twin one presented in emergency at life hour 7 with complaints of respiratory difficulty stabilized and admitted to NICU. On examination his heart rate was 148 per minute and respiratory rate was 66/m.SpO2 was 86% without oxygen and 96%with oxygen. The baby improved within 24 hours and a diagnosis of transient tachypnoea of newborn was labeled. Other systemic examinations were unremarkable. Head circumference was 30 cm and length was 41 cm with upper segment 25 cm and lower segment 16 cm. Right thigh was thick, plump and shortened (Figure 1) and on x-ray right femur was not visualized and the hip and knee joints were malformed (Figure 2).

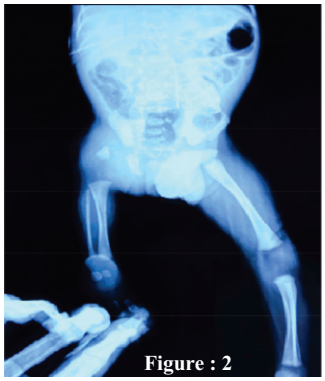

Figure 1: Malformed Right Lower Limb
Figure 2: Right Hip & Knee joint Malformation

Complete blood counts of the baby were normal with hemoglobin 19.2 gm/dl, hematocrit 56.3%, Total leucocyte counts 12.2 with normal differentials, MCV 110.6, RDW 18.8 and CRP negative. Serum urea was 13 mg/dl and creatinine was 1.02mg/dl. Serum electrolytes and calcium were normal and blood culture was sterile. USG abdomen, USG brain, and 2D-ECHO were normal.

MRI pelvis and right thigh done for detailed evaluation revealed dysplastic right acetabular cavity. Right femur not visualized. Tibia and fibula showing pseudo articulation with acetabular cavity with posterosuperior dislocation of head of tibia. Marked wasting of muscles noted around right hip joint and thigh. Right knee joint was also malformed and the upper margins of tibia and fibula were dysplastic (Figure-3). Left hip joint, left femur and left leg bones were normal.

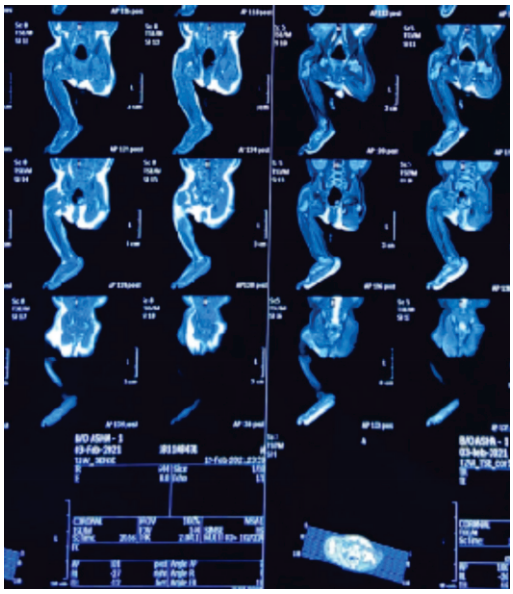

Figure 3: MRI pelvis and bilateral lower limbs

Twin 2 – had weight 1.3 kgs. His blood sugar was 69 mg/dl and SpO2 was 98 %. His CRT was normal and general physical examination and systemic examinations were unremarkable except for hypothermia. The other twin didn't have any congenital malformation and his x rays werenormal. His hemoglobin was 14.5 gm /dl with hematocrit 43.5%. TLC was 7000 with normal differentials and CRP was negative. MCV was 115.7 and RDW 18.1. S urea, creatinine and electrolytes were normal. Blood group of both twins was AB positive.

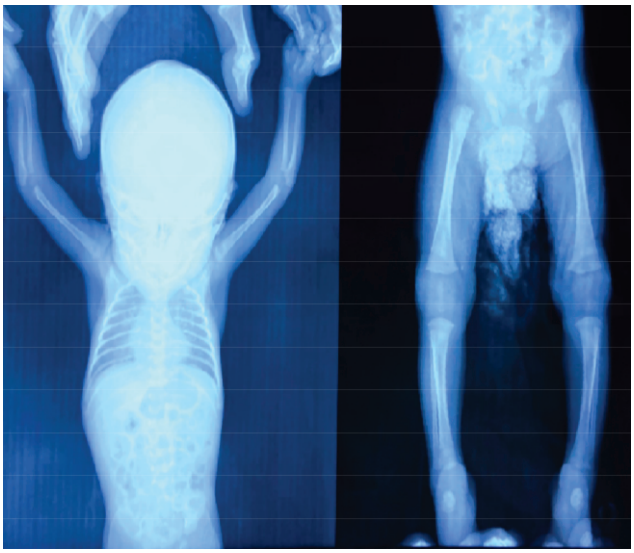

Figure 4: Twin secondInfantogram

DISCUSSION

In congenital femoral defects,the clinical examination should be careful and directed towards detecting associated abnormalities. Cleft palate, congenital heart defects, vertebral abnormalities, microcephaly were also cited in association with PFFD, even in up to 70% of the cases[2-4]. Absence of craniofacial abnormalities differentiates PFFD from FHUFS[5]. We are reporting dysplastic right acetabular cavity, upper ends of tibia and fibula with congenital absence of femur. Craniofacial configuration of both the twins was normal in our case. Proximal femoral focal deficiency or postaxial femoral dysplasia, a very rare defect was described first time by Kalamchi[6]; noticed at birth, occurring in 1/50.000-1/200.000 live births[2, 6]. The short, deformed, and dys-functional femur is characteristic of this condition[7]. In 15% of the cases, PFFD occurs bilaterally but without gender or familial predilection[3, 8]. Both the twins in our case are male.

In more than half of the cases, there is simultaneously a longitudinal defect of the fibula, often also a shortening of the tibia. The patella is often dysplastic and sometimes lateralized. The knee is usually in a valgus deformity. More rarely, the opposite side or one of the upper extremities is also affected. The historical classification by Aitken[4] is followed later by a more comprehensive classification of Pappas[5], and a modern classification proposed by Paley, associated with the term "congenital femoral deficiency"[9,10]. In the early stages, the non-ossified structures can be detected on ultrasound, by MRI or arthrography. A short femur may need to be evaluated thoroughly in order to exclude a series of conditions that may evolve with short femur: skeletal dysplasia (achondroplasia, hypo-chondroplasia, kyphomelic dysplasia, camptomelic dysplasia, tanatophoric dysplasia, achondrogenesis, Spryntzen syndrome, etc.), aneuploidies (as Down syndrome or monosomy X, Turner syndrome), metabolic syndromes (osteogenesis imperfecta), intrauterine fractures, caudal regression syndrome[11].

Prenatal diagnosis is important -Femoral length is routinely measured during fetal biometry starting the second trimester[2]. Prenatally, a short femur is defined as a femur length less than the 5th percentile for the gestational age or under 2 standard deviations for the gestational age on ultrasound[12]. If a short femur length is identified prenatally, all the long bones must be measured and evaluated for length disproportions and discrepancies must be searched[13]. A ratio less than 1 between the femoral length and the rest of the lower limb may suggest a skeletal dysplasia[13]. Correct evaluation of the gestational age is mandatory in order to avoid false positive results[12]. Fetal limbs can be seen on fetal ultrasound from the 10th week, the skeleton and the hands and legs can be evaluated from the 13-14th week of gestation[13]. In suspected cases, the fetal ultrasound must be followed by other tests, as amniocentesis, etc. in order to frame defect and exclude other anomalies (as chromosomopathies)[13]. We recommend regular fetal biometry during antenatal visits. Also, a short femur, is diagnosed prenatally may have to be distinguished from a naturally short femur in intrauterine growth restriction associated with utero-placental insufficiency, situation in which the femur length must be evaluated in correlation to limb length[14]. Severe intrauterine restriction associated with short femur must be distinguished from Russell-Silver syndrome.

Surgical correction of the short femur aims obtaining stability, ambulation, optimal functioning, and better cosmetic appearance[3,8]. Uncorrected, femoral hypoplasia leads to increased energetic consumption during walking, scoliosis and secondary pain, stress fractures, and unaesthetic appearance and walking[2]. Various treatment options are available, including shoe elevation, orthotic or prosthetic devices, realignment osteotomy, arthrodesis, rotationplasty, amputation and surgical leg lengthening. Complex deformities should be treated by a team of specialists such as orthopedic surgeons, orthotists, physiotherapists, psychologists and possibly other surgeons too.

CONCLUSION

As the etiology of limb malformations is unclear; this report will add to the body of available knowledge. This report is unique as only one twin was affected. We are more interested in management issues like applying the classification, counselling of parents and multidisciplinary team-based approach. We recommend to develop an interdepartmental protocol for managing such cases.

REFERENCES

1. Vasluian E, van der Sluis CK, van Essen AJ, Bergman JEH, Dijkstra PU, ReindersMesselink HA, de Walle HEK. Birth prevalence for congenital limb defects in the northern Netherlands: a 30-year population-based study. BMC Musculoskeletal Disorders 2013; 14:

323-33.

2. Doger E, Köpük FI, Çakiroglu Y, Çakir O, Yücesoy G. Unilateral Isolated Proximal Femoral Focal Deficiency. Case Reports in Obstetrics and Gynecology. Volume 2013, Article ID 637904.
3. Ellul M, Chircop M, Grixti C, Grech V. Proximal femoral focal deficiency - a case report. Malta Medical Journal 2008; 20: 42-3.
4. Aitken GT: Proximal femoral focal deficiency Definition, classification, and management. In: Aitken GT, ed. Proximal Femoral Focal Deficiency. A Congenital Anomaly. Washington, DC: National Academy of Sciences; 1969
5. Pappas AM Congenital abnormalities of the femur and related lower extremity malformations: classification and treatment. J Pediatr Orthop. 1983;3:45-60.
6. Kalamchi A, Cowell HR, Kyung IK. Congenital deficiency of the femur. J PediatrOrthop.1985; 5: 129-34.
7. Bronstein M, Deutsch M. Early diagnosis of proximal femoral deficiency. Gynecologic and Obstetric Investigation 1992; 34(4): 246-8.
8. Siddiqui YS, Abbas M, Zahid M, Asif N. Congenital short femur Clinical Presentation. Saudi Med J 2012; 33(4): 455-6.
9. Paley D (1990) Problems, obstacles, and complications of limb lengthening by the Ilizarov technique. Clin OrthopRelat Res. 1990;250:81-104.
10. Paley D, Standard SC Treatment of congenital femoral deficiency. In: Wiesel SW (ed) Operative techniques in orthopaedic surgery. Lippincott Williams & Wilkins, Philadelphia, pp. 2010;1202-23.
11. Keskin D, Ezirmik N, Karsan O. Congenital bilateral short femur complicated by stress fracture. A case report. Acta Orthopaedica Belgica 2000;66(5): 499-502.
12. Makino Y, Inoue T, Shirota K, Kubota S, Kobayashi H, Kawarabayashi T. A case of congenital familial short femur diagnosed prenatally. Fetal Diagn and Ther 1998; 13(4): 206-8.
13. Korber F, Schonau E, Horwitz EA, Benz-Bohm G. Isolated femoral hypoplasia: an intrauterine differential diagnosis to campomelia. PediatrRadiol 2005; 35: 641646.
14. Ugurlucan FG, Kayserili H, Yuksel A. Prenatal Evaluation of Fetuses Presenting with Short Femurs, Prenatal Diagnosis - Morphology Scan and Invasive Methods, Dr. Richard Choy (Ed.), ISBN: 978-953-51-0614-2, InTech, 2012;

   Available from: http://www.intechopen. com/books/prenataldiagnosismorphology-scan-and-invasivemethods/prenatal-evaluation-of-fetuses presenting-with-short-femurs.